

Patient information

Metatarsus adductus

Metatarsus adductus is a common foot condition in babies and young children. Normally, the outside border of the foot is straight. In metatarsus adductus, the outside border of the foot curves inwards, resulting in a bean-shaped appearance (figure 1). Metatarsus adductus is thought to be related to the position of the baby in the mother's uterus and can affect one or both feet.

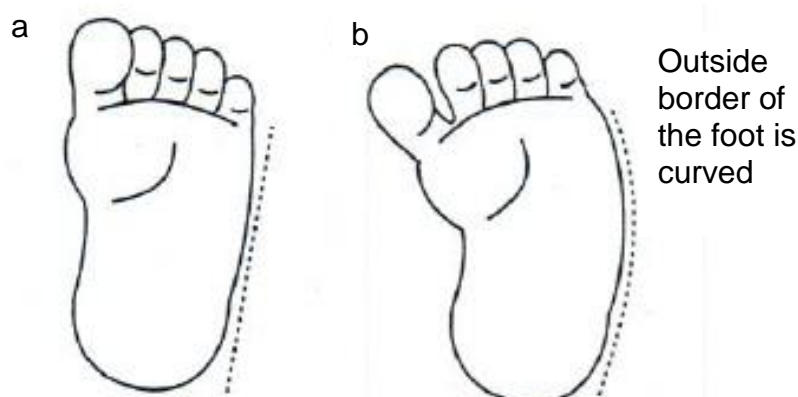


Figure 1: (a) normal foot (b) Metatarsus adductus

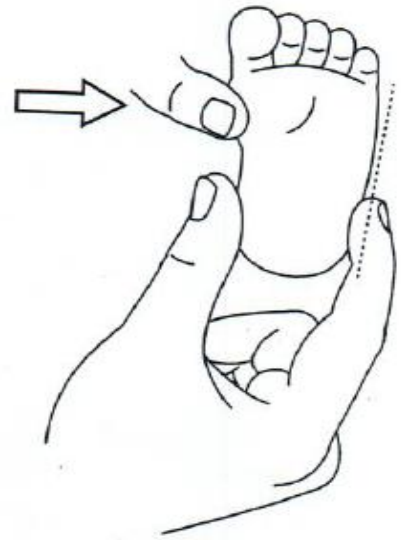In most babies, affected feet stay flexible and the condition resolves over the first two to three years without treatment.

Some babies and young children with metatarsus adductus need assessment and monitoring by the child's doctor, child health nurse or physiotherapist. Gentle exercises may help. These should be performed regularly. Exercises are most effective when the baby or child is relaxed and should never be painful. In rare cases treatment may be needed. This may consist of a series of casts, special braces or shoe inserts.

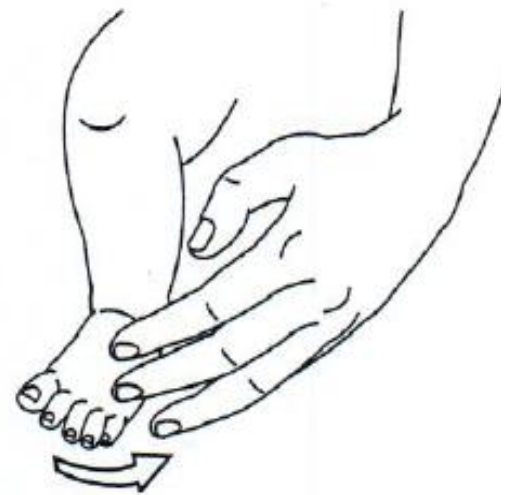A baby with metatarsus adductus should have a careful hip examination. If you are concerned that the foot is stiff or not improving, consult your child's doctor or physiotherapist.

Exercises

- 1 Gently move the front of your baby's foot outwards so it is straight. This may be held for a few seconds so it is straight. This may be held for a few seconds, or longer if your baby is comfortable.



- 2 Gently stroke the outside and front of your baby's foot and lower leg to encourage the foot into a normal position.



If you would like any information regarding access to the West Suffolk Hospital and its facilities please visit the hospital website www.wsh.nhs.uk and click on the link, or visit the disabledgo website:

<http://www.disabledgo.com/organisations/west-suffolk-nhs-foundation-trust/main>